

# The Evolution of Remote-Controlled Intramedullary Lengthening and Compression Nails

Stuart A. Green, MD

**Summary:** The operative elongation of limbs has long been a goal of orthopaedic surgeons. Indeed, the very first external skeletal fixators, although designed for stabilization of displaced fractures, were also used to overcome the posttrauma shortening that so commonly accompanies fracture deformities.

**Key Words:** distraction osteogenesis, Ilizarov method, intramedullary lengthening nail, Fitbone, PRECICE, PRECICE UNYTE, UNYTE

(*J Orthop Trauma* 2017;31:S2–S6)

In 1895, Clayton Parkhill of Denver Colorado devised the world's first external skeletal fixator.<sup>1</sup> His earliest published articles show the device being used to restore length to a mal-united femur that had healed short, in bayonet apposition (Fig. 1).

At around the same time, Alessandro Codivilla, an Italian surgeon, created a windlass type apparatus for limb elongation<sup>2</sup> (Fig. 2). A generation later, in 1921, Putti used a simple monolateral external fixator and a step-cut osteotomy to gradually elongate bones<sup>3</sup> (Fig. 3).

Leroy Abbott, of San Francisco, in 1939, followed Putti's principle of a step-cut osteotomy but used a more stabilized external fixator that had 2 transfixation pins in each bone fragment<sup>4</sup> (Fig. 4).

In the 1950s, Bost and Larsen, working at a Shriners' Children's Hospital in the San Francisco area, began using external skeletal fixation to lengthen bones in pediatric deformities.<sup>5</sup> They often used an intramedullary nail to maintain alignment. In some of their cases, they observed new bone formation in the widening distraction gap without the need for bone grafting (Fig. 5).

A decade later, Dr Heinz Wagner created a monolateral external fixator for limb lengthening that incorporated a telescopic mechanism to elongated bones.<sup>6</sup> A knob at one end of

the device lengthened the fixator (Fig. 6). He used a rate and rhythm of 1 mm per day in one step. Typically, at the end of elongation, a bone graft was inserted into the widened distraction gap and a plate applied to the surface of the bone for stabilization purposes. The fixator was removed at the same operative procedure. The results were somewhat unpredictable.

A revolution in limb lengthening occurred in 1951 when Soviet surgeon G. A. Ilizarov unlocked from within bone a previously hidden capacity to form unlimited new osseous tissue under appropriate conditions of osteotomy, stabilization, and highly fractionated distraction.<sup>7</sup> His circular external fixator, secured to a limb's bone by tensioned wires, proved axially dynamic (like a trampoline) but stable in all other planes (Fig. 7). His clinic, starting out as a veteran's health care facility in a log cabin in Siberia, evolved into the world's largest orthopaedic hospital. Three hundred fifty orthopaedic surgeons, all specifically trained in the Ilizarov Method, cure numerous maladies previously considered untreatable.

Over the years since Ilizarov's discoveries about new bone formation in a widening bone gap, surgeons began to devise ways to apply Ilizarov's method of distraction osteogenesis while simultaneously eliminating the cumbersome and often painful circular fixator.

Bliskunov of the Ukraine devised the first practical intramedullary lengthening femoral nail.<sup>8</sup> The implant consists of a telescopic nail elongated by an internal ratchet system. To power the ratchet, Bliskunov connects one end of the device (via a universal joint) to the outer wall of the iliac crest. By internally and externally rotating the hip, the nail elongates (Fig. 8). The implant is still in use in Eastern Europe.

The Albizzia Nail came next. It too contains a ratchet mechanism, but it is powered by counter-rotation of the fragments on both sides of an osteotomy with respect to each other.<sup>9</sup> The nail, locked with transverse screws into each fragment, telescopes outward, lengthening the limb. Because 30 degrees of rotation is necessary to effect the elongation, the mechanism can cease to be effective if the regenerate new bone becomes too stiff to allow so much counter-rotation. This, in turn, means a return trip to the operating room for the patient for reosteotomy through the regenerate. Nevertheless, the Albizzia Nail remains popular in Europe, especially in France, where it was developed.

Dean Cole, MD of Orlando created the internal skeletal kinetic distractor (ISKD).<sup>10</sup> Like the Albizzia Nail, the ISKD is powered by counter-rotation of the fragments, but only a few degrees are necessary to ratchet out the implant, the amount that typically occurs during walking. A clutch

Accepted for publication March 9, 2017.

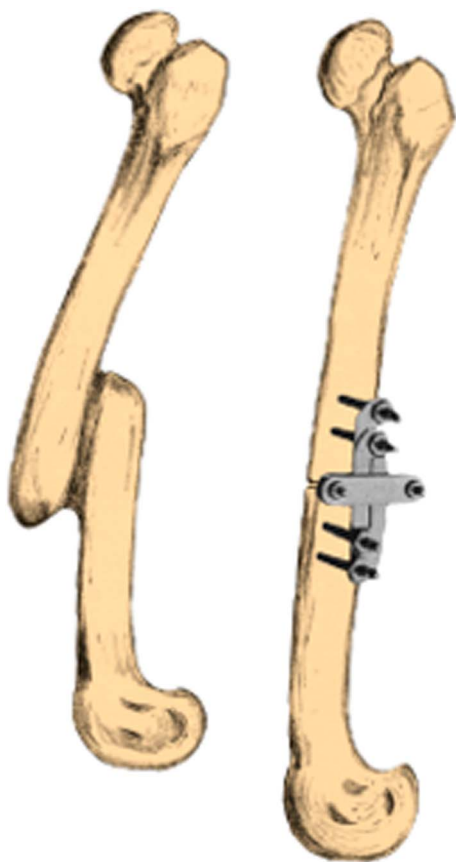
From the Department of Orthopaedic Surgery, School of Medicine, University of California, Irvine, Orange, CA.

The author receives royalties from, and serves as a consultant for, NuVasive Specialized Orthopedics and receives royalties from Smith & Nephew.

Reprints: Stuart A. Green, MD, Department of Orthopaedic Surgery, School of Medicine, University of California, Irvine, 101 The City Drive South, Orange, CA 92868 (e-mail: sgreen@uci.edu).

Copyright © 2017 The Author(s). Published by Wolters Kluwer Health, Inc. This is an open-access article distributed under the terms of the Creative Commons Attribution-Non Commercial-No Derivatives License 4.0 (CCBY-NC-ND), where it is permissible to download and share the work provided it is properly cited. The work cannot be changed in any way or used commercially without permission from the journal.

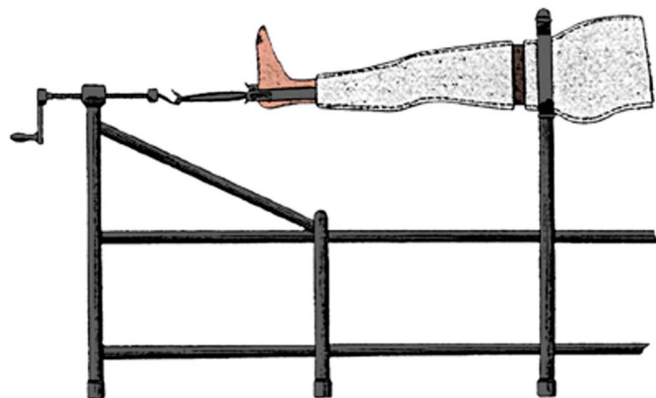
DOI: 10.1097/BOT.0000000000000844



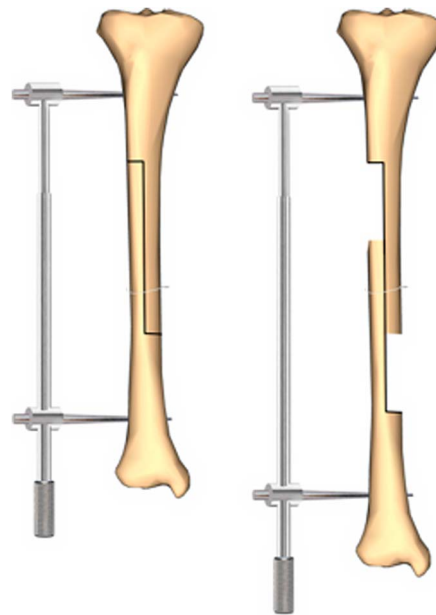
**FIGURE 1.** Parkhill bone clamp. Used with permission copyright @ ZEECA Publishing Company, Long Beach, CA.

mechanism releases the ratchet during each step, allowing it to elongate the device and limb.

The principle problem with the ISKD is occasional too rapid lengthening once the postoperative pain diminishes, potentially causing poor regenerative formation, as well as neurovascular difficulties manifest at first by tingling and later by numbness.

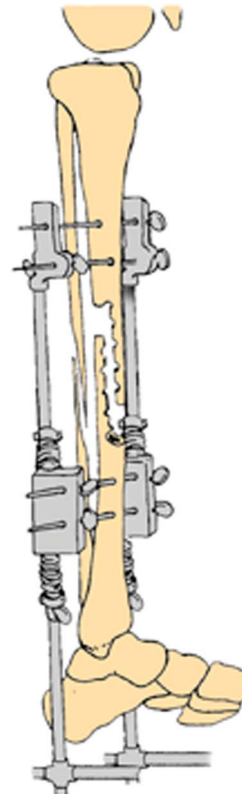


**FIGURE 2.** Codivilla windlass for limb elongation. Used with permission copyright @ ZEECA Publishing Company, Long Beach, CA.

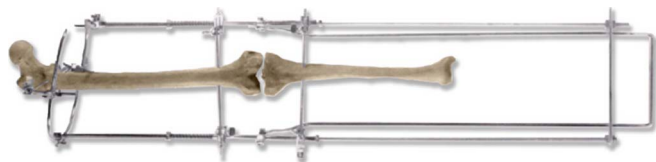

**FIGURE 3.** Putti lengthening technique. Used with permission copyright @ ZEECA Publishing Company, Long Beach, CA.

The first mechanical, motor-driven intramedullary lengthening nail was the Fitbone developed by Rainer Baumgart<sup>11</sup> in Germany. It contains an electric motor but no battery. Instead, the motor is powered by electricity transmitted via an induction



**FIGURE 4.** Abbott external fixator. Used with permission copyright @ ZEECA Publishing Company, Long Beach, CA.



**FIGURE 5.** Bost and Larsen limb lengthener. Used with permission copyright @ ZEECA Publishing Company, Long Beach, CA.

coil placed underneath the skin (Fig. 9). A second induction coil placed on the exterior surface of the body adjacent to the internal coil transmits electricity to the implant. It has been used successfully all over the world but is not approved by the FDA for use in the United States as of this writing.

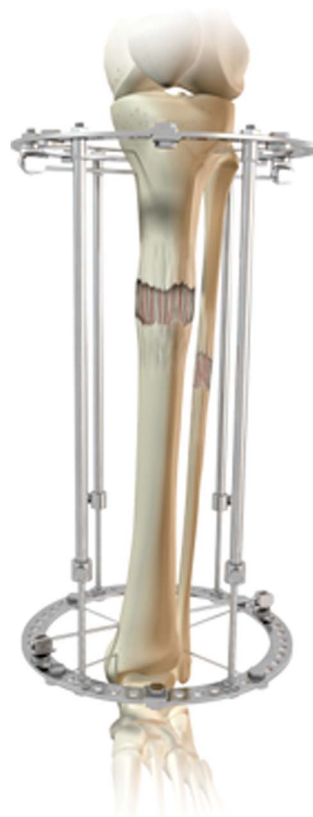The PRECICE intramedullary lengthening nail contains a rare earth magnet affixed to a spindle.<sup>12</sup> The magnet rotates in response to rotating external magnets placed about 2 inches away, outside the skin. A series of 3 planetary gears provide a 1:64 gear ratio, enough to elongate the implant against considerable resistance (Fig. 10).

The PRECICE nail can be used in both a distraction and a compression mode; indeed, the ability to temporarily reverse the lengthening of the implant is particularly appealing, especially if the elongation is causing neurovascular problems or pain issues for the patient.

During the development phase of the implant, which evolved from a spinal lengthening rod, animal studies confirmed that the quality of bone formed during distraction after Ilizarov principles of fractionated elongation of 1 mm



**FIGURE 6.** Wagner lengthener. Used with permission copyright @ NuVasive, Inc., San Diego, CA.



**FIGURE 7.** Ilizarov circular external fixator. Used with permission copyright @ NuVasive, Inc., San Diego, CA.

per day in three or 4 steps resulted in new osseous tissue that had all of the histologic characteristics of distraction regenerate using Ilizarov circular fixator (Fig. 11).

The initial implant was assembled from separate components with multiple weld points that proved to be stress risers and occasional broken implants. As a result, the manufacturer eliminated the welds and inserted the entire lengthening assembly into a solid tube, thereby essentially eliminating the risk of implant failure because of breakage.

The preliminary success of the PRECICE intramedullary lengthening nail, and especially its acceptance by patients, who have previously endured limb lengthening with an external skeletal fixator, has caused surgeons to seek ways to eliminate external fixators altogether in complex limb reconstruction surgery.<sup>13</sup>

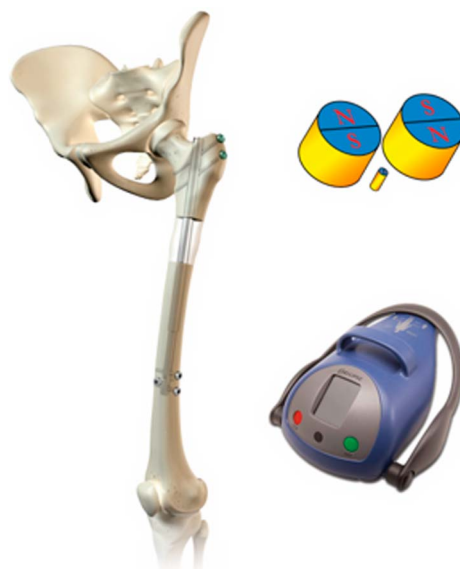There is thus evolving a new treatment paradigm in deformity correction surgery that involves either simultaneous or sequential operations to first eliminate the deformity by subtraction wedge osteotomy, and secondarily, to restore a limb length with an internal lengthening nail. In some cases, these 2 objectives can be achieved at one site in the bone by performing an osteotomy through the apex of the deformity and realigning the fragments along an intramedullary nail.

We are learning, however, that too much correction of deformity in the distraction zone inhibits regenerate formation. Moreover, it seems that the tibia is more sensitive to attempted deformity correction than is the femur. Thus, there



**FIGURE 8.** Bliskunov intramedullary lengthening nail. Used with permission copyright @ NuVasive, Inc., San Diego, CA.

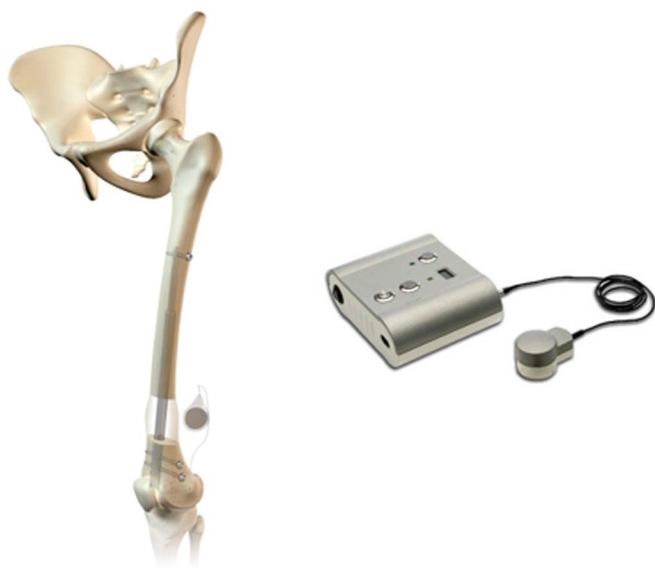is an emerging consensus that trying to correct more than 5–10 degrees of deformity in any plane in the tibia will inhibit regenerate formation, whereas the femur can tolerate up to 15 degrees of deformity correction.



**FIGURE 10.** PRECICE intramedullary lengthening nail. Used with permission copyright @ NuVasive, Inc., San Diego, CA.

It may be possible, by prolonging the latency interval (the time after osteotomy, before beginning distraction), slowing down the speed of distraction to 0.5 mm per day, and increasing the number of steps per day, to have a satisfactory experience lengthening through a zone of deformity correction.

Once a technology evolved that could predictably elongate bone with an intramedullary nail, it became obvious to many of us that such implant might also be used for compression osteosynthesis of fresh fractures and nonunions. To do so, the implant has to be prelengthened before



**FIGURE 9.** Fitbone intramedullary lengthening nail. Used with permission copyright @ NuVasive, Inc., San Diego, CA.



**FIGURE 11.** New bone formation in sheep femur distracted by PRECICE nail. Used with permission copyright @ NuVasive, Inc., San Diego, CA.

insertion, so there is enough travel of the telescopic portion of the nail to allow compression.

Clearly, when treating nonunions, compression osteosynthesis is most predictably effective with hypertrophic nonunions—those that display a proliferative bone response on both sides of the fracture line. Such nonunions respond favorably to compression with an external skeletal fixator or compression with a bone plate and screws. Under the circumstances, there is no reason to assume that such a nonunion should not respond favorably to interfragmentary compression achieved with an intramedullary nail. If the respective bone fragments are coaxial, then inserting an intramedullary nail is a far simpler procedure than applying a complex multiplanar external fixator or a large compression plate to the surface of a bone. Moreover, reaming the medullary canal as part of the intramedullary nail procedure has its own salutary effect on bone healing.

Next, we get to the matter of fresh fractures. Compression osteosynthesis has long been a feature of the operative treatment of displaced and unstable fractures. For the most part, this is accomplished with compression plates and intrafragmentary compression screws. There have been, in the past, attempts to create an intramedullary compression nail. Typically, a standard intramedullary nail is inserted into the bone, and the transverse locking screw is secured between the distal end of the nail and the distal fragment. Next, some kind of plunger is placed over the insertion end of the nail (which had been buried deeper into the bone than usual), and the plunger is used to provide counter-pressure on the bone, whereas the nail is withdrawn until fragmentary compression is achieved at the fracture site. Then, the proximal locking screw or screws are inserted and the plunger device is removed.

As with compression plates, such a compression nail provides static intrafragmentary compression. The only way to have dynamically adjustable compression is to use an external skeletal fixator for compression osteosynthesis.

With the availability intramedullary nails containing a motorized spindle and telescopic components, adjustable and repeatable intrafragmentary compression is now possible. The technique will be described by Dr. Watson in this symposium.

Lastly, we come to the matter of bone transport, a technique for overcoming segmental skeletal defects that has, heretofore, been the exclusive domain of external skeletal fixators, especially Ilizarov-type circular devices. Bone transport is particularly painful for patients because the wires used to move the intercalary segment cut through the skin by creating pressure necrosis along the leading edge of the transcutaneous implants. For this reason, strategies are evolving to achieve bone transport with an entirely internalized system.

## REFERENCES

1. Parkhill C. I. Further observations regarding the use of the bone-clamp in ununited fractures, fractures with malunion, and recent fractures, with a tendency to displacement. *Ann Surg.* 1898;27:553–570.
2. Codavilla A. On the means of lengthening in the lower limbs, the muscles and tissues which are shortened through deformity. *Am J Orthop Surg.* 1905;2:353.
3. Putti V. Operative lengthening of the femur. *Surg Gynecol Obstet.* 1934; 58:318–324.
4. Abbott LC, Saunders JB. The operative lengthening of the tibia and fibula. *Ann Surg.* 1939;110:961–991.
5. Bost FC, Larsen LJ. Experiences with lengthening the femur over an intramedullary rod. *J Bone Joint Surg Am.* 1956;38A:567–584.
6. Wagner H. Operative lengthening of the femur. *Clin Orthop Rel Res.* 1978;136:125–142.
7. Ilizarov GA. A method of uniting bones in fractures and an apparatus to implement this method. 1952. USSR Authorship Certificate. Report No.: 98471.
8. Bliskunov AI, inventors; Variable Lengthening Device and Method. US patent 8,852,187 B2. October 7, 2014.
9. Guichet JM. Leg lengthening and correction of deformity using the femoral Albizzia nail [in German]. *Orthopade.* 1999;28:1066–1077.
10. Cole JD, Justin D, Kasparis T, et al. The intramedullary skeletal kinetic distractor (ISKD): first clinical results of a new intramedullary nail for lengthening of the femur and tibia. *Injury.* 2001;32(suppl 4):SD129–SD139.
11. Baumgart R. The reverse planning method for lengthening of the lower limb using a straight intramedullary nail with or without deformity correction. A new method. *Oper Orthop Traumatol.* 2009;21: 221–233.
12. Pool S, Green SA, Roschak E. inventors; ellipse technologies, assignee. *Variable Length Device and Method.* USA: 2012.
13. Rozbruch SR, Birch JG, Dahl MT, et al. Motorized intramedullary nail for management of limb-length discrepancy and deformity. *J Am Acad Orthop Surg.* 2014;22:403–409.