

Stryde Weight-bearing Internal Lengthening Nail

Craig Robbins, MD and Dror Paley, MD, FRCSC

Summary: Since May 2018, 106 patients (187 limb segments) have completed internal lengthening with the Stryde implant. Fifty-seven skeletally mature patients (12 female and 45 male) underwent cosmetic stature lengthening of the femur (41), tibia (4), or combined bilateral femur and tibia (12). Forty-nine other patients (ages 9 to 60 y) with a variety of limb length discrepancy etiologies including metabolic, congenital, genetic, and post-traumatic, underwent unilateral lengthening of the femur (37) or tibia (12). All patients undergoing lengthening alone were allowed immediate full weight-bearing as tolerated. Patients with secondary ipsilateral acute deformity corrections had restricted weight-bearing until sufficient healing was present at the metaphyseal site. The mechanical axis deviation following lengthening was not statistically significantly related to limb segment, patient weight, nail diameter, or distraction amount, but tended towards varus in the femurs and valgus in the tibias. Fifty-two stature patients and 43 unilateral patients lengthened to within 10 and 5 mm of their goals, respectively. One tibial nail stopped functioning prematurely and was exchanged to complete the lengthening. Seven patients required secondary unplanned operations. Successful outcomes were achieved in all patients. Strict adherence to careful preoperative planning, and postoperative lengthening protocols including specialized limb lengthening physiotherapy are important to the success. There were no issues related to biological incompatibility of the Biodur 108 alloy stainless steel from which the implant was fabricated.

Key Words: Precice—Stryde—stature—lengthening—weight bearing—cosmetic—internal—height.

(*Tech Orthop* 2020;35: 201–208)

Ellipse Technologies (Irvine, CA) developed the PRECICE nail with a team of surgeons under the direction of Dr Stuart Green. It was Food and Drug Administration (FDA) cleared August 23, 2011.^{1,2} The Precice (P1) was first implanted in the United States by one of the authors (D.P.) on December 1, 2011. It was a titanium alloy telescopic locking nail. To obtain 510K clearance as quickly as possible, Ellipse Technologies used the same dimensions and materials as the predicate device (ISKD; Orthofix, McKinney, TX). They deviated from the Orthofix by making this first nail modular (exchangeable proximal locking segment) and by housing the mechanism within an intercalary separate segment welded to the rest of the nail. The modular junction, affixed with a setscrew, sometimes disengaged from the rest of the nail when it was being removed.¹ The welds became the site of occasional breakage of the nail during the consolidation phase. Furthermore the original mechanism occasionally failed if it met too much resistance. The failure was at the junction of the lead screw with the part of the nail called the thrust bearing. To reduce the risk of

failure, patients had to restrict weight-bearing by using wheelchair and crutches during elongation and maturation of the regenerate.

Ellipse redesigned the mechanism, which was released in May 2013. This new mechanism strengthened the junction of the lead screw with the thrust bearing by 3 times and added a clutch to the mechanism so it would not break upon meeting excessive resistance. They also redesigned the body of the nail, eliminating the modularity and welds. The larger diameter nail segment was now one single segment tube. This made the nail 4 times stronger in dynamic 4 point bending (the failure mechanism that lead to nail breakage previously). It was also 2 times stronger in tensile strength. This new nail was referred to as the P2 and was designed by company engineer Scott Pool and one of the authors (D.P.) and was first implanted in November 2013. The rate of nail breakage dropped significantly. In one report comparing P1 to P2 the rate of failure dropped from 12.1% (7/58 P1: 4 nail fracture; 3 mechanism failure) to 1.7% (1/58 P2: 1 nail fracture).²

Although the welds were eliminated from the body of the nail, the P2 incorporated 4 spot welds to hold the crown (a rotational control mechanism) in place at the end of larger nail tube, at the junction where the smaller nail tube exits. In bending the most highly stressed part of the nail is this junction. The crown tended to crack or break frequently without nail failure but occasionally contributed to nail breakage. The Orthofix ISKD also used a crown with a weld in its design which also proved to be the site of failure for the ISKD.³ The Precice P2 nail was redesigned by the same team to eliminate the welds to the crown. An internal crown was developed. This next model was the P2.1 and was released in December 2014.⁴ A small number of the P2.1 developed a failure of the thrust bearing connection as related to rotation leading to unexpected shortening (winding backwards) of the lead screw during the consolidation phase. This led to the most recent design of the Precice nail. The P2.2 was released in mid-2015. All of the current Precice nails are the P2.2, referred to herein below as P2. It is available in 8.5, 10.7, and 12.5 mm diameters. Extensive clinical experience with the different diameters of Precice 2 nails has provided objective weight-bearing restriction guidelines; 8.5 and 10.7 mm nails: 50 lbs (22.7 kg) and 12.5 mm nails: 75 lbs (34 kg). This means patients must use a walker for bilateral applications and crutches for unilateral applications. Most patients therefore use a wheelchair for longer distances and crutches or walker for shorter distances.

Both the Precice and the ISKD its predecessor are titanium alloy nails. Both require restriction of weight-bearing. In contrast, the Albizzia nail, which predates both of these nails, is a cobalt chrome nail and full weight-bearing as tolerated is permitted.⁵ Similarly, the Fitbone nail, which is a stainless steel implantable lengthening nail, allows full weight-bearing as tolerated. There are few reports of nail breakage with these implants.^{6–8}

In 2014, Ellipse Technologies began a new project to create a full weight-bearing nail with one of the authors (D.P.). The impetus was specifically for bilateral lengthening cases (lengthening for stature). Three options were considered: increasing the wall thickness of the titanium nail, versus change

From the Paley Orthopedic and Spine Institute, West Palm Beach, FL. D.P. has a conflict with Nuvasive. C.R. declares no conflict of interest.

For reprint requests, or additional information and guidance on the techniques described in the article, please contact Dror Paley, MD, FRCSC, at dpaley@paleyinstitute.org or by mail at The Paley Orthopedic & Spine Institute, 901 45th Street, West Palm Beach, FL 33407. You may inquire whether the author(s) will agree to phone conferences and/or visits regarding these techniques.
Copyright © 2020 Wolters Kluwer Health, Inc. All rights reserved.

of material to either cobalt chrome or stainless steel. In 2016, Ellipse was acquired by Nuvasive (San Diego, CA). The development of a full weight-bearing nail was continued. The decision not to use cobalt chrome was 2-fold: (1) cobalt chrome is very difficult to machine, increasing the cost significantly (2) the junction of the tube and rod elements of the telescopic nail could theoretically produce metal ions, which are already known to be toxic from experience with cobalt chrome steel.⁹

Therefore, the decision was made to make a stainless steel nail using Biodur 108 alloy stainless steel (per ASTM F2229), chosen for its strength. Both the nail and locking screws would be made from this alloy. The nail was strengthened by increasing the overlap between the outer tube and inner rod. In addition to the material changes, the crown was replaced by an antirotation lug. The magnet was also increased in length to increase the distraction force by 18.6%. This allows for wider tissue gap between the external remote control and the nail ranging from 45 mm for the 10 mm diameter to 65 mm for the 11.5 mm diameter and 85 mm for the 13 mm diameter. The locking screws, instead of being smooth pegs threaded for the near cortex only, are also threaded for the far cortex with a thread diameter equal to the diameter of the peg. This requires a step drill to avoid over drilling of the far cortex before inserting the transverse locking screws. This innovative design preserves the strength of having a peg (larger outer diameter compared with a fully threaded screw) while allowing for threaded purchase on the near and far cortex. The new nail was called the Stryde. When comparing the strength of the 3 diameters of the Precice nail with the 3 comparable diameters of the Stryde nail, the latter was found to be significantly stronger [1.3 to 1.5 times stronger in 4 point bending yield load; 2 to 2.5 times stronger in 4 point bending fatigue load; and about 2.2 times stronger in ultimate distraction torque (N-m)]. Based on these tests Nuvasive Specialized Orthopedics recommends a maximum patient body weight for each nail diameter as follows: 10 mm <150 lbs (68 kg); 11.5 mm <200 lbs (91 kg); and 13 mm <250 lbs (114 kg). The Stryde nail was first implanted in May 2018 by one of the authors (D.P.).

STRYDE NAIL TECHNIQUE

The surgical technique for the Stryde nail is identical to that for the Precice P2 except for the special drill bits required for the locking screws. The Stryde nail comes in 10, 11.5, and 13 mm diameters. The Stryde nail comes in 5, 6.5, and 8 cm lengthening stroke corresponding to minimal lengths of 235, 250, and 265 mm. The 8 cm stroke nail is available in longer lengths (280, 305, 335, and 365 mm). The Stryde nail for the femur also comes in trochanteric and piriformis entry configurations. There is only one configuration for the tibia.

The level of osteotomy is calculated the same way as for Precice. The upper and lower ends of the nail are marked on the skin depending on the length of nail chosen. Measuring retrograde from the lower end of the nail, mark the lowest permissible level of the osteotomy, which is the sum of the total amount of desired lengthening, plus 3 cm of planned overlap, plus 3 cm (representing the amount of the inner lengthening rod protruding from the outer tube). This will ensure that at least 3 cm of overlap of the outer tube is within the bone segment on the other side of the distraction gap.

FEMUR ANTEGRADE

Piriformis nails are preferred in skeletally mature patients. Trochanteric nails are used in skeletally immature patients or those whose anatomy precludes a piriformis nail.

Authors' Preferred Technique

Step 1: Position patient supine on radiolucent operating table and prep and drape up to the ribs with the leg free.

Step 2: Mark the level of the tip of the greater trochanter on the skin. Measure from that point the desired length of the nail and mark its lower end. Measure back from there (as described above) to identify the lowest permissible level of the osteotomy. Make the osteotomy at any point proximal to that level.

Step 3: Make a lateral stab wound at the level of planned osteotomy and use the 4 or 5 mm drill bit to make multiple drill holes at the osteotomy level. First make one entrance and 3 exit holes and then make 2 additional entrance holes so that you now have a total of 6 holes drilled in the femur. These will allow decompression of the canal to avoid fat embolism and will also allow the reamings to graft the osteotomy site.

Step 4: Insert a Steinmann pin percutaneously into the proximal medial tip of the greater trochanter or into the piriformis fossa with the leg adducted. Confirm with image intensifier on anteroposterior and lateral views.

Step 5: Make a 15 mm incision around the pin and ream open the starting point with a 10 mm anterior cruciate ligament reamer.

Step 6: Insert the beaded guide rod down the femur.

Step 7: Ream the femur in 1 mm increments until there is chatter and then reduce to half millimeter increments. Ream 2 mm greater than the diameter of the nail to be used (eg, 12 mm for 10 mm nail, 13.5 mm for 11.5 mm nail, 15 mm for 13 mm nail).

Step 8: Insert the selected Stryde nail down to the level of the planned osteotomy.

Step 9: Two assistants are needed to support the limb: one holds onto the foot and supports it in the air with traction and without rotating the foot. The leg should not touch anything that could give it support. The other holds the nail with its introducer and lifts towards the ceiling to create an extension moment arm.

Step 10: With the extension moment in place use an osteotome through the lateral incision to osteotomize the femur percutaneously. Once the bone is heard to break, test that it is broken by gently applying a valgus and varus stress and watching it bend with fluoroscopy. (The surgeon applies one hand on the lower leg and one on the handle of the nail. Both assistants continue the extension moment while allowing the surgeon to stress the osteotomy site. No loss of rotation occurs since the anterior cortex of the bone is under compression from the extension moment and traction.)

Step 11: The nail is advanced down the femur crossing the osteotomy site. Once it is safely on the other side, the assistant holding the leg lowers it down to rest on the table while maintaining traction. The nail is advanced until its upper end is at the level of the top of the piriformis fossa or seated in the greater trochanter for piriformis versus trochanteric nails, respectively.

Step 12: Lock the nail proximally with the locking screw insertion jig. Mark the skin with the drill sleeves for the proximal 2 holes. Then make one skin incision that will be used for both drill holes. Drill the more distal proximal screw first. This makes sure that you start on the greater trochanter and do not move down into the concavity at its base where it is more difficult to start. Use the step drill and drill both cortices. Do not allow the drill to advance past the second cortex. Insert the Stryde screw using power on the ream setting. Now drill the most proximal of the proximal screws.

Step 13: Free hand lock the distal holes after creating perfect circles on the image intensifier in the lateral position.

Insert a bayonet tipped wire into the 2 distal holes. Use a cannulated drill for the first cortex and then drill the second cortex with a solid step drill. Insert the first lower locking screw and then repeat the process for the second one.

Step 14: Curette out the remainings from the proximal nail incision.

Step 15: No blocking screws are needed except if the osteotomy is very proximal, above the level of the isthmus. If needed, insert a medial blocking screw using the Precice pegs.

Step 16: All the incisions are closed.

Femur soft tissue releases: For cosmetic stature lengthening of the femur the iliotibial band (ITB) and intermuscular septum should be transected together with a biceps aponeurosis recession. This is performed through a 3 cm lateral distal thigh incision at the level of the proximal pole of the patella.⁴ Care is taken not to cause bleeding from the lateral geniculate artery. For congenital cases the fascia lata is transected at the level of the greater trochanter through a small incision in addition to the distal ITB and biceps releases. Posttraumatic and developmental cases may not need the ITB and biceps cut unless they have a positive Ober sign and large popliteal angle.⁴

TIBIA ANTEGRADE

Authors' Preferred Technique

Step 1: Position the patient supine on a radiolucent table.

Step 2: Make a 3 cm posterolateral incision in the midcalf and cut the fibula subperiosteally. Expose the fibula between the gastrocnemius and peroneal muscles. Drill holes in the fibula with a bayonet tipped wire and then use a small diameter osteotome to complete the osteotomy. If there is need for a peroneal nerve decompression,¹⁰ then first do the decompression and then expose the neck of the fibula and cut the bone under direct vision with a saw and osteotome.

Step 3: Mark the proximal and distal ends of the nail on the skin and the planned level of the osteotomy.

Step 4: Flex the knee maximally and insert a Steinmann pin medial parapatellar into the superior surface of the tibial plateau. Do not start in the space between the joint line and the tuberosity.

Step 5: Use an anterior cruciate ligament reamer to create the starting hole.

Step 6: Insert the beaded guidewire down the tibia.

Step 7: Ream the tibia 2 mm greater than the desired nail diameter.

Step 8: Remove the guidewire and lay the leg flat and supine.

Step 9: Make a 1 cm incision over the planned osteotomy level and make multiple drill holes at that level with a 4 mm drill bit.

Step 10: Use an osteotome to complete the osteotomy; try not to propagate the osteotomy proximally or distally.

Step 11: Flex the knee again and insert the Stryde nail.

Step 12: Lock the nail proximally with 3 locking screws using the step drill.

Step 13: Remove the proximal locking guide and free hand lock the distal end with the leg supine again. Lock with 2 screws using the cannulated wire method described for the femur.

Step 14: Insert a lateral blocking screw in the proximal segment using a Precice peg. Insert a posterior blocking screw using a Precice peg to prevent procurvatum if the rod is not touching the posterior cortex.

Step 15: Insert a distal tibiofibular screw. Insert a wire from the fibula to the tibia inclined from distal to proximal. Exit

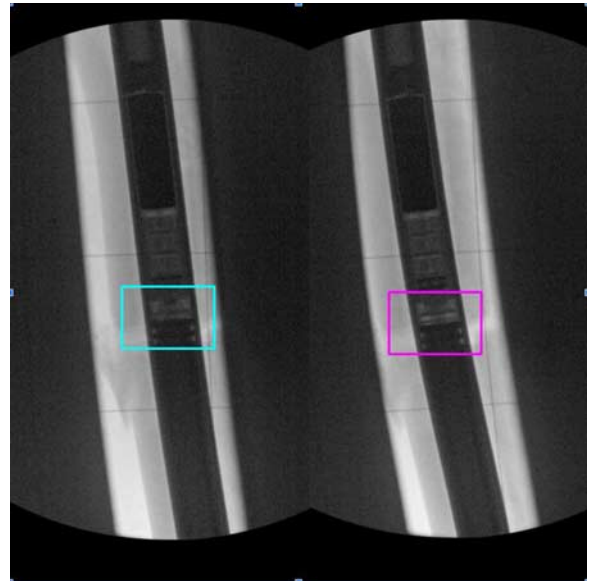


FIGURE 1. Intraoperative fluoroscopic images of Stryde lengthening nail. Turquoise box shows mechanism before (left) and fuchsia box shows mechanism after (right) 1 mm of lengthening. Although the Stryde nail is more radio-opaque than the Precice since the stainless steel is more radio-opaque than titanium, it can still be imaged adequately to see the space inside the housing for measurement purposes.

out the medial side and use another wire to measure the length. Drill with a cannulated drill from the medial side and insert a Precice peg from medial to lateral.

Step 16: Insert a proximal tibiofibular screw using a Precice peg. Insert a bayonet wire from the tibia to the neck of the fibula by rotating the leg till the 2 are overlapping under lateral fluoroscopy. Drill over this wire with a cannulated drill and then insert a Precice peg from medial to lateral.

Step 17: Curette the remainings from the nail insertion incision.

Step 18: All the incisions are closed.

Soft tissue releases for the tibia: Achilles tendon lengthening¹¹ and gastro-soleus aponeurosis lengthening¹² should be avoided so as not to weaken push-off. The latter is preferred over the former. Temporary arthrodesis of the ankle joint using an extra-articular screw can be used to rigidly immobilize the ankle at 90-degree to avoid equinus.¹³ This is the internal analog of extending an external fixator to the foot during tibial lengthening.

Before waking the patient, the nail is tested by lengthening 1 mm acutely. High-resolution magnified fluoroscopic images of the lengthening mechanism are taken before and after this lengthening. Although the stainless steel Stryde is more radiopaque than the titanium Precice, by adjusting the contrast the same detail of the mechanism can be seen (Fig. 1).

POSTOPERATIVE ROUTINE

Epidural or peripheral nerve block or patient controlled analgesia using narcotics can be used for up to 2 days postoperatively. After that, the patient is switched to oral medication which can include narcotic agents (oxycodone, hydrocodone), acetaminophen and anti-inflammatory medication. Beginning at discharge or at most a week later, only acetaminophen.

To prevent hematoma in the first 12 hours after surgery, especially if the iliotibial is cut, an elastic bandage can be used.

In the tibia or around the knee, cryotherapy is useful to prevent excessive swelling. It is also important to elevate the limb to reduce dependent swelling. Mechanical deep venous thrombosis prophylaxis is recommended. A daily aspirin starting 24 hours after surgery is also used until the patient is ambulating normally.

The patient is mobilized the day after surgery. Weight-bearing is tolerated in patients with Stryde nails. The patient learns to stand and then walk with a walker. The patient learns transfers from bed to chair and back. It is essential for patients to learn to transfer to a bedside commode or the toilet. Patients are taught to walk up and down steps before discharge so that they can negotiate stairs in their home environment.

For tibial lengthening it is important to prevent the foot from laying in an equinus posture. Off the shelf or, preferably, custom dorsiflexion splints are used to keep the Achilles under stretch at all times. This is used for all tibial lengthening cases unilateral and bilateral. To prevent flexion contracture or subluxation of the knee during femoral lengthening a hip-knee-ankle-foot orthosis brace can be used at night to keep the knee in extension. This is only done with congenital cases. This is not done with bilateral or noncongenital unilateral cases.

LENGTHENING

Distraction begins 1 week after surgery. The rate of distraction depends on the bone (femur, tibia, humerus, forearm etc.), its diameter, the indication for lengthening (congenital, developmental, posttraumatic leg length difference, stature lengthening), normal or dysplastic patients, and other factors such as simultaneous femur and tibia lengthening.

The smaller the bone diameter, the slower should be the lengthening. For example, the femur and tibia and humerus all have large diameters and therefore can be lengthened between 0.75 and 1.0 mm per day. The forearm and metatarsals and metacarpals have small diameters and should only be lengthened at 0.5 mm per day. Very young children have smaller diameter bones than older children and therefore the lengthening rate should be slower for younger children: 1 mm per day for older children versus 0.75 mm for younger children.

The femur heals faster than the tibia and therefore, in general, the femur can tolerate 1 mm per day compared with 0.75 mm for the tibia. Congenital leg length difference should be lengthened slower than developmental or posttraumatic cases due to its susceptibility to contracture and joint subluxation.

Certain pathologic bone conditions have increased or decreased bone healing potential. Ollier disease, for example, has an increased bone healing ability resulting in premature consolidation, while bone in neurofibromatosis patients has a decreased healing ability. Similarly, the bone in achondroplasia or hypochondroplasia has a more rapid healing than the normal bone of cosmetic stature lengthening patients. Simultaneous ipsilateral lengthening of the femur and tibia lengthens the vessels, nerves and skin faster than when only a single bone is being lengthened. This can lead to pain, dysesthesias, or paresis, requiring nerve decompression surgery either prophylactically or therapeutically. In such cases, the femur should not be lengthened faster than 0.75 mm per day and the tibia 0.5 mm per day. Since lengthening does not start until a week after surgery (latency period), the patient or their family is taught to use the external remote control device after discharge from hospital.

PHYSICAL THERAPY

Outpatient physical therapy is started after discharge. This consists predominantly of passive stretching exercises focusing

on maintaining knee and ankle motion. At the hip, maintaining passive abduction helps prevent adduction contracture and hip subluxation. In the tibia, the principle stretch is to the gastrosoleus muscles to maintain the ankle at least at 90-degree so that the foot remains plantigrade. Active motion is important mostly for the hip abductors and the quadriceps.

Progression from use of a walker to no walking aids begins in physical therapy. In the first 2 to 3 weeks, patients are sore from the small incisions that were made in their leg or thigh. This gives them pain when they contract their muscles. Although some of them could walk without the walker or crutches, most would be at-risk of falling down. The therapist judges when these patients are safe to walk without walking aids. They then do a single leg standing test onto a floor scale. They observe the maximum step up weight. To do this, the patient steps up on the affected limb and the therapist observes the maximum weight registered on the scale. This corresponds to the maximum weight seen by the nail during single leg stance. As long as this is less than the amount allowed for that specific nail, the patient can walk without crutches or a walker. We do recommend they carry a single cane for use on stairs and curbs.

TIPS FOR SUCCESS

Have informed discussions about the logistics and expectations for limb lengthening with the patient and their family before surgery.

Discuss postoperative pain management before surgery.

Establish well-defined protocols and communication channels with physical therapists.

Anticipate and prevent complications such as contractures and compartment syndrome.

Consider the sagittal femoral bow and level of osteotomy to accommodate the straight nail.

Postoperative lengthening x-ray analysis:

Is there lengthening?

Is it appropriate for the rate and duration of lengthening?

Is it symmetric (bilateral)?

AVOID PITFALLS AND CHALLENGES

Have adjacent nail sizes (diameters and lengths) and end caps available in the operating room.

If staged, perform ipsilateral tibial surgery before femur surgery because tibias move slower, heal slower, and require knee hyper-flexion to place nail.

Acutely lengthen the nail 1 mm in the operating room to ensure the mechanism functions; consider reversing the test-length in "at-risk" patients.

Consider prophylactic nerve releases, soft tissue releases, and fasciotomies.

Place the distal upper screw through the proximal femoral jig first. Occasionally the drill bit will deflect distally and miss the nail. In this event the surgeon will drive the nail deeper until the drill aligns and place the distal then proximal screw.

CLINICAL EXPERIENCE WITH STRYDE WEIGHT-BEARING NAILS

Methods

Institutional Review Board approval was obtained for this retrospective review. Data were obtained from a consecutive series of 106 patients who underwent placement of 187 Stryde nails between May 17, 2018 and October 10, 2019 and completed lengthening and consolidation (Tables 1, 2). Measurements included: level of

TABLE 1. Demographics Mean (Range)

Limb Segments	Age (y)	Weight (kg)	Height (cm)
Stature female	29.1 (15-63)	50.8 (44-60)	155 (139-172)
Stature male	31.5 (16-56)	69.3 (36-98)	165.4 (147-179)
Unilateral female	21.9 (9-55)	53.6 (34-75)	153.8 (134-173)
Unilateral male	24.7 (9-60)	68 (43-107)	166.5 (143-188)

osteotomy, length gained, femoral-tibial angle, lateral distal femoral angle (LDFA), medial proximal tibial angle, and mechanical axis deviation for preoperative and postoperative EOS or standing alignment x-rays.

Fifty-seven skeletally mature patients (12 female and 45 male) underwent cosmetic stature lengthening: bilateral femur (41), tibia (4), or combined femur and tibia (12) (Fig. 2). All bilateral femur lengthenings were antegrade piriformis and all bilateral tibial nailings were antegrade. Forty-nine patients (21 female and 28 male) with leg length discrepancy of various etiologies underwent unilateral lengthening: femur (37); tibia (12). Femur lengthening was done by trochanteric start point in 18 (Fig. 3), piriformis in 12 and retrograde (using piriformis nail) in 7. Tibial lengthenings were antegrade in 7 and retrograde (using piriformis nail) in 5 when lengthening was done in a patient with an ankle fusion or undergoing an ankle fusion (Fig. 4).

RESULTS

One hundred six patients (187 limb segments) completed internal lengthening with the Stryde implant. All patients were allowed immediate full weight-bearing unless contra-indicated by concurrent procedures (15 unilateral cases; eg, metaphyseal angular correction, ankle fusion, temporary arthrodesis of ankle). Fifty-two of 57 stature patients and 43 of 49 unilateral patients lengthened to within 10 and 5 mm of their preoperative goal respectively (Table 2). One tibial nail failed and stopped lengthening in a patient with bilateral femur and tibial lengthening. The affected tibial nail was exchanged to complete the lengthening. This was later confirmed to be a failure at the site of the thrust bearing. Despite the same weight-bearing on the other tibial and 2 femoral nails, only 1 tibial nail mechanism failed.

All patients/limb segments completed consolidation of the regenerate bone. There were no nonunions and no patient required secondary procedures to treat delayed or nonunion of the regenerate. There were no issues related to biological incompatibility of the Biodur 108 alloy stainless steel from

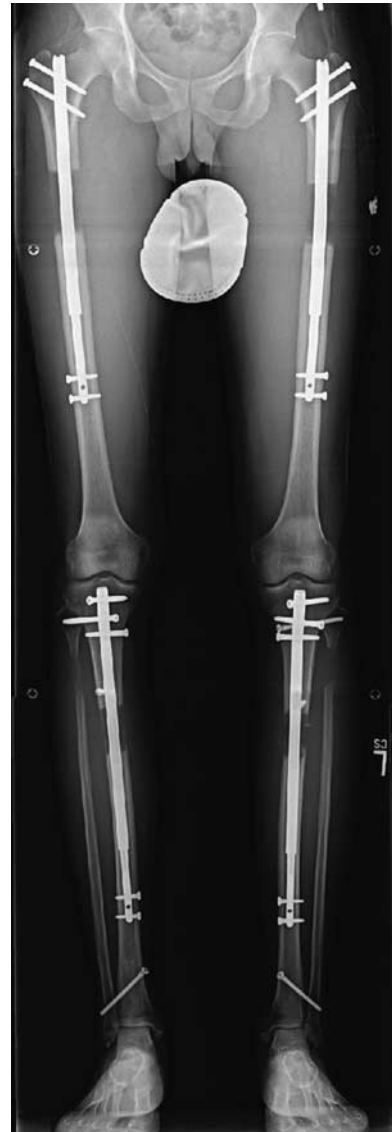

FIGURE 2. B.S. is a 39-year-old 164 cm in height, 64 kg male who desired 10 cm lengthening in femurs and tibiae. His femur surgery was 3 weeks after his tibia surgery. He achieved 5.8 cm in the femurs and 4.2 cm in the tibiae for a total of 10 cm. Note the inclination of the distal tibia-fibular fixation pegs. Proximally the tibia-fibular fixation was with a locking screw on the right and a separate peg on the left.

TABLE 2. Patients Not Reaching Goal (Within 1 cm for Stature and 0.5 cm for Unilateral)

Reason for Stopping Lengthening	Segment/Diagnosis	Achieved (cm)	Goal (cm)	% of Goal
Decrease knee ROM	Stature femurs	5	8	63
Decrease knee ROM	Stature femurs	6	8	75
Fracture	Stature femurs	6	8	75
Decrease knee ROM	Stature femurs	6.5	8	81
Decrease ankle ROM	Stature tibiae	3	5	60
Peroneal nerve palsy	Femur/CFD	2	6	33
Decrease knee ROM	Femur/arthrogryposis	4.4	7.2	31
Premature consolidation	Femur/malunion	1.7	2.7	63
Decrease knee ROM	Retrograde femur/CFD	3.6	5	72
Decrease knee ROM	Femur/septic emboli	5.6	7	80
Knee subluxation	Femur/CFD	4	5	80

CFD indicates congenital femoral deficiency; ROM, range of motion.

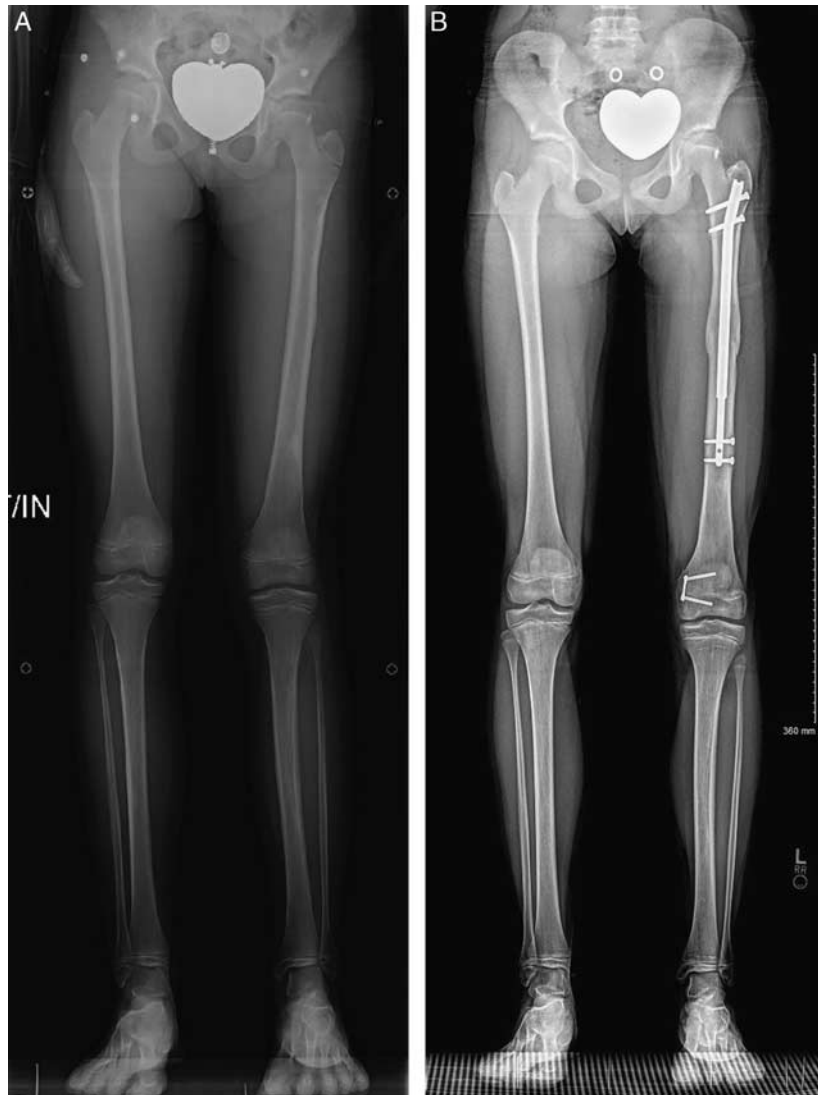

FIGURE 3. A, D.B. is a 12-year-old child with left congenital femoral deficiency, fibular hemimelia, and genu valgus who has previously undergone left femur external fixator lengthening. She had a predicted leg length discrepancy of 3.8 cm at skeletal maturity and underwent left medial distal femur hemiepiphysiodesis and left antegrade femur lengthening with a trochanteric Stryde implant. B, D.B. several months postoperative. Equal leg length and normal alignment achieved.

which the implant was fabricated. There was no corrosion seen in the few nails that were removed during this short study time.

Seven patients required unplanned operations to treat complications (Table 3). Nonoperative complications included: 1 unilateral femur lengthening patient developed an ipsilateral deep venous thrombosis with symptomatic pulmonary emboli 6 weeks after surgery, and was managed successfully medically; 1 bilateral femur stature patient had a persistent 5 cm area of numbness on the anteromedial leg below the knee that resolved with time; and one 4 segment stature patient has drop big toe due to paralysis of the extensor hallucis longus that persisted despite peroneal nerve decompression.

Statistical analysis of alignment data revealed no correlation between preoperative and postoperative measurements of femoral-tibial angle, medial proximal tibial angle, or LDFA in the bilateral cases. The magnitude of LDFA change trended with the amount of length gained but not the direction.

Alignment in unilateral cases was not studied since most had open physes with hemiepiphysiodesis to treat alignment, concurrent realignment osteotomy, or significant residual limb length discrepancy requiring future surgery including alignment correction.

DISCUSSION

There is little debate about the advantages of implantable limb lengthening versus external fixator lengthening for most indications. There are still some limitations to the use of implantable devices related to length and diameter of the bones, presence of growth plates and stability of joints. Excluding these cases, one of the main advantages touted for external fixation is the ability to allow weight-bearing as tolerated to the patient. The risk of failure of the mechanism or nail has limited comparable weight-bearing freedom with the Precice nail.²

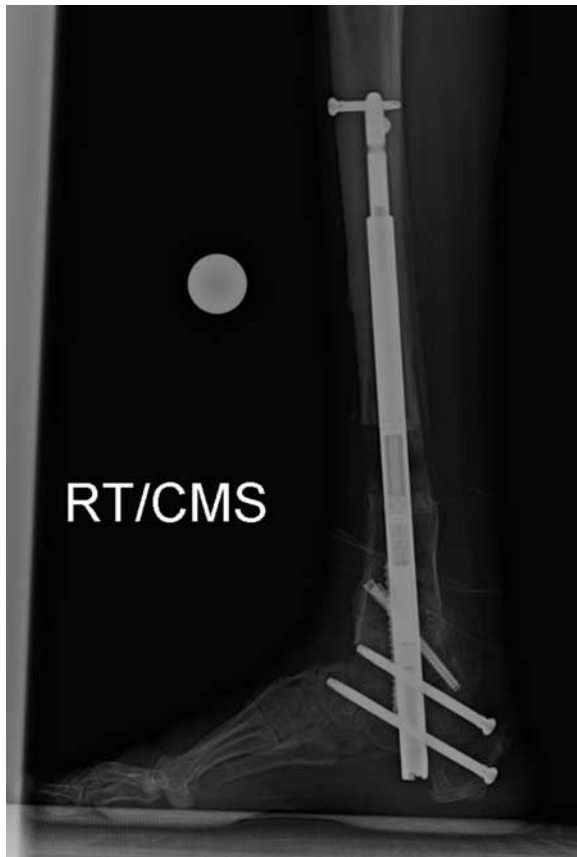


FIGURE 4. E.C. is a 49-year-old male with sequelae from polio and previous surgeries with a 3.5 cm leg length difference and a painful, stiff varus ankle and hindfoot. He underwent hardware removal, realignment with ankle fusion and retrograde tibia lengthening with a piriformis Stryde implant. He had restricted weight-bearing for 6 weeks until the ankle fusion was healed enough to allow full weight-bearing. This is a lateral x-ray 3 months after surgery with a 2.5 cm lengthening. RT indicates right.

The Stryde nail was developed to permit unrestricted weight-bearing during both the distraction and consolidation phases. Other devices such as the ISKD, Albizzia, and Fitbone

permit weight-bearing as tolerated only during the consolidation phase.⁶⁻⁸

This is the first report on the results of the full weight-bearing Stryde nail. It is important to note that there were no structural breakages of the Stryde in 187 nails. There was one tibial nail mechanism that failed during the distraction phase. It is unclear why this happened especially considering the same patient had Stryde nails in the other tibia and both femurs at the same time, all of which continued to function normally. The ultimate test of a nail is in bilateral simultaneous lengthening. Unilateral lengthening cases can protect the lengthened side by favoring their intact limb. Bilateral cases literally “do not have a good leg to stand on.” Therefore since all the bilateral cases in this study were able to ambulate with full weight-bearing both during the distraction and consolidation phase without the need for wheelchair or walking aids (exception: we do recommend a single cane be used for curbs and stairs), without bending or breaking their nails and with only one mechanism failure, indicates that the Stryde nail is strong enough to meet the loads of walking both during distraction and consolidation. The Stryde is the first lengthening nail in which such ambulation freedom is encouraged and permitted. Although external fixation patients are allowed weight-bearing as tolerated most of them use crutches or a walker during much of the treatment. The Stryde patients only used these walking aids in the first 3 weeks after surgery.

Immediate postoperative weight-bearing has many potential benefits. It allows for more aggressive physical therapy including unrestricted gait training. This is expected to lead to less muscular atrophy and faster return to normal walking compared with patients on prolonged weight-bearing restrictions. Patients have free functional use of their upper extremities when they are not being utilized for walker or crutches. Patients also do not need to use anticoagulation for lengthy periods of time if they are full weight-bearing. Weight-bearing likely also stimulates better bone healing. Future studies will hopefully document these advantages objectively.

CONCLUSIONS

Immediate full weight-bearing with the Stryde nail is safe during limb lengthening. There have been no issues of biological incompatibility with the Biodur 108 alloy stainless steel from which the implant was fabricated.

TABLE 3. Unplanned Secondary Surgery

Complication	Segment/Diagnosis	Treatment	Achieved (cm)	Goal (cm)	% of Goal
Fracture of femur	Stature femurs	FAN static nail exchange	6	8	75
Premature consolidation both femurs	Stature femurs	Repeat osteotomy femurs	6.5	6.5	100
Tibia nail mechanism failure	Stature femurs and tibias (4 segments)	Repeat osteotomy and nail exchange	5.2	5	104
Bending of distal T-F fixation screw	Stature tibias	Revision distal T-F screw	5.5	5.5	100
Loosening of distal locking screw	Femur/malunion	Exchange locking screw	3	3	100
Peroneal nerve palsy	Femur/CFD	Nerve decompression	2	6	33
Drainage from soft tissue release site	Femur/arthrogyposis	I&D, wound closure	3.7	3.7	100

CFD indicates congenital femoral deficiency; FAN, fixator-assisted nail; I&D, irrigation and debridement; T-F, tibio-fibular.

REFERENCES

1. Paley D. PRECICE intramedullary limb lengthening system. *Expert Rev Med Devices*. 2015;12:231–249.
2. Paley D, Harris M, Debiparshad K, et al. Limb lengthening by implantable limb lengthening devices. *Tech Orthop*. 2014;29:72–85.
3. Burghardt RD, Herzenberg JE, Specht SC, et al. Mechanical failure of the intramedullary skeletal kinetic distractor in limb lengthening. *J Bone Joint Surg Br*. 2011;93-B:639–643.
4. Paley D, Debiparshad K, Balci H, et al. Stature lengthening using the PRECICE intramedullary lengthening nail. *Tech Orthop*. 2015;30:167–182.
5. Guichet J-M, Casar RS. Mechanical characterization of a totally intramedullary gradual elongation nail. *Clin Orthop*. 1997;337:281–290.
6. Küçükkaya M, Karakoyun Ö, Sökücü S, et al. Femoral lengthening and deformity correction using the Fitbone motorized lengthening nail. *J Orthop Sci*. 2015;20:149–154.
7. Guichet J-M, Deromedis B, Donnan LT, et al. Gradual femoral lengthening with the Albizzia intramedullary nail. *J Bone Joint Surg Am*. 2003;85:838–848.
8. Singh S, Lahiri A, Iqbal M. The results of limb lengthening by callus distraction using an extending intramedullary nail (Fitbone) in non-traumatic disorders. *J Bone Joint Surg Br*. 2006;88-B:938–942.
9. Green B, Griffiths E, Almond S. Neuropsychiatric symptoms following metal-on-metal implant failure with cobalt and chromium toxicity. *BMC Psychiatry*. 2017;17:33.
10. Nogueira MP, Paley D. Prophylactic and therapeutic peroneal nerve decompression for deformity correction and lengthening. *Oper Tech Orthop*. 2011;21:180–183.
11. Lamm BM, Paley D. Percutaneous Z Tendon Achilles Lengthening. In: Scuderi GR, Tria AJ, eds. *Minimally Invasive Surgery in Orthopedics*. New York, NY: Springer New York; 2010:433–434.
12. Lamm BM, Paley D, Herzenberg JE. Gastrocnemius soleus recession: a simpler, more limited approach. *J Am Podiatr Med Assoc*. 2005;95:18–25.
13. Belthur MV, Paley D, Jindal G, et al. Tibial lengthening: extraarticular calcaneotibial screw to prevent ankle equinus. *Clin Orthop*. 2008;466:3003–3010.